

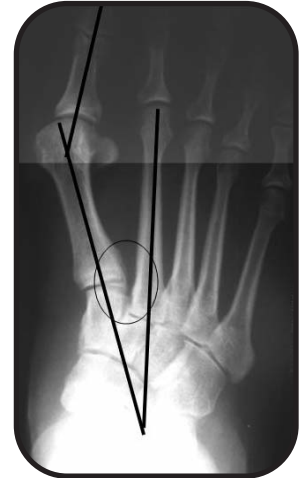Lapidus Bunion Correction

V. James Sammarco, MD
Cincinnati Sports Medicine and Orthopaedic Center
Cincinnati, OH

Clinical Presentation

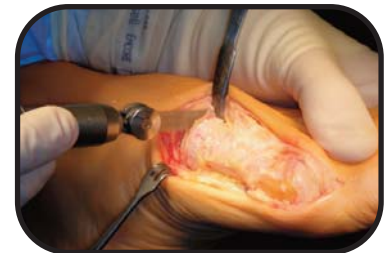This 42 year old woman presented with a symptomatic Bunion deformity. The pre-operative physical examination revealed instability of the first tarsometatarsal joint with lesser metatarsal phalangeal joint pain and prominence. Other deformities included interphalangeal joint flexion deformities. Surgery was elected by the patient due to recalcitrant pain despite conservative management.

Pre- operative X-Rays demonstrated 1st TMT instability in association with a widened intermetatarsal angle and hallux valgus deformity. Note gapping between the first and second metatarsal bases. The lapidus procedure was selected for correction of the bunion due to the high intermetatarsal angle and instability of the first TMT joint.

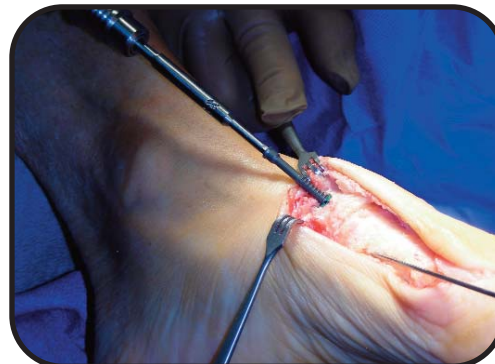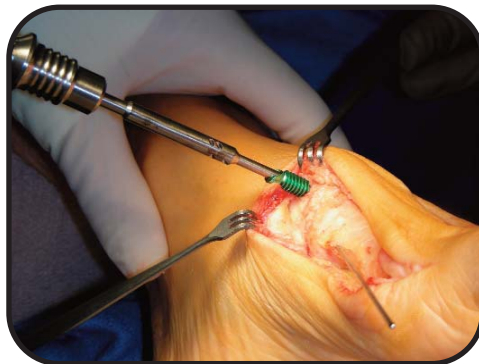


Surgical Management

A medial approach was used for arthrodesis of the first tarsometatarsal joint, resecting the articular surfaces with a micro-sagittal saw. The intermetatarsal angle was corrected by incorporating a medial closing wedge into the resection. Note: more bone was resected laterally than medially to allow for bone apposition and correction of the IMA

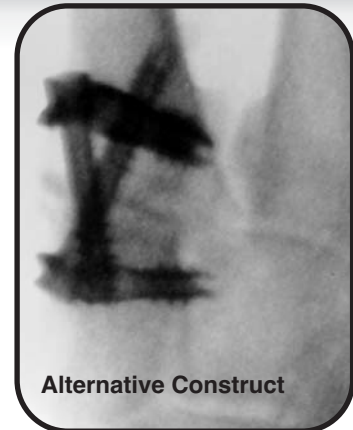
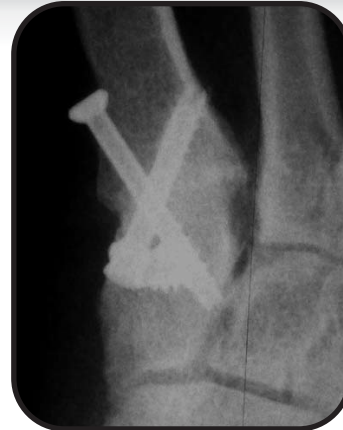
Temporary fixation was achieved by pinning the joint in the corrected position with a Kirschner wire. Rigid compression of the arthrodesis was achieved with a IO-Fix construct where the X-Post was applied in the medial cuneiform and a lag screw applied through the eyelet and driven into the proximal 1st metatarsal. The screw locked into the eyelet of the post with a morse taper creating a fixed angle device.



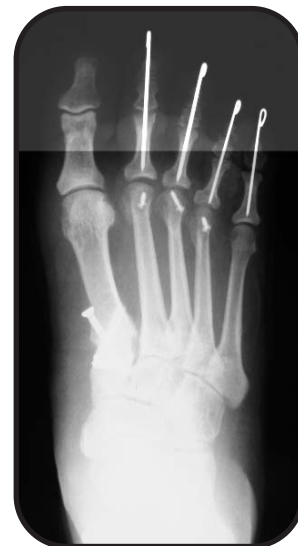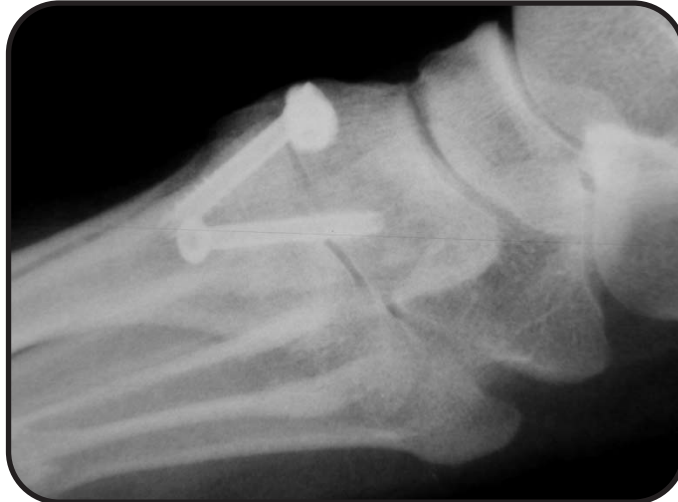A second screw was used for additional fixation from distal to proximal.

Note: A second IO FIX can be utilized to greatly increase the strength of the fixation for the at risk patient.



The hallux metatarsal phalangeal joint was corrected by lateral soft tissue release and medial capsular plication. The forefoot was balanced by shortening and elevating the lesser metatarsal heads with Weil type osteotomies. Digital deformities were corrected by resection arthroplasty of the lesser interphalangeal joints.

Post-Operative radiograph showed rigid compression of the arthrodesis with the IO-Fix device and a crossed screw. Durable deformity correction was achieved. Correction of the lesser metatarsal parabola was achieved with distal osteotomies



Outcome

The patient was made non-weight bearing for two weeks, and then allowed to weight bear on her heel in a rigid soled post-op shoe. Full weight bearing and return to normal shoe wear was allowed at 6 weeks when radiographic union was apparent. The IO-FiX device afforded rigid, stable fixation of the 1st TMT arthrodesis without bridging the devices into the second metatarsal or middle cuneiform. This improved fixation in turn allowed for early mobilization in a simple post without casting or extended periods of non-weight bearing, and eventually produced a successful, durable correction.