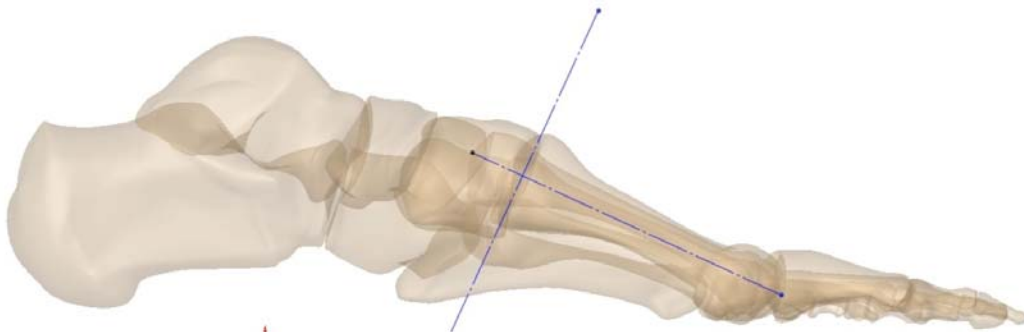


## TMT Fusion / Lapidus

### Quick Technique Recommendations (eliminates the need for the alignment guide)

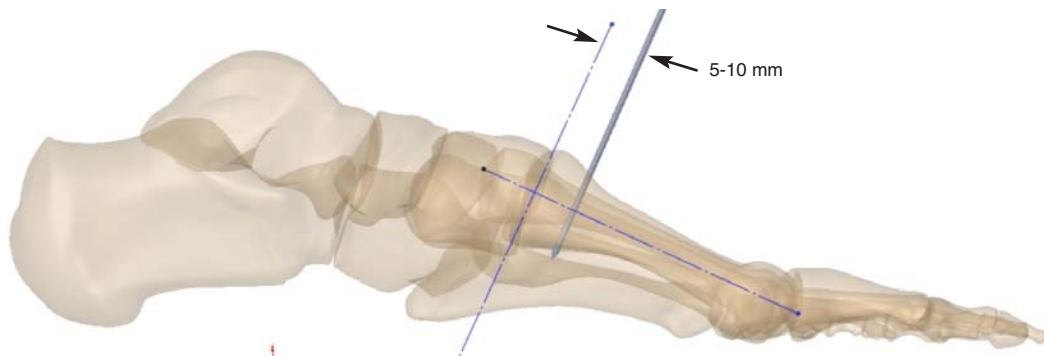
#### 1. Pre-operative plan for X-Post placement

- a. Template: perpendicular lines - apex of the joint/center of the bone
  - i. If X-Post placement is Dorsal/Plantar - use ML View
  - ii. If X-Post placement is Medial/Lateral - use AP View

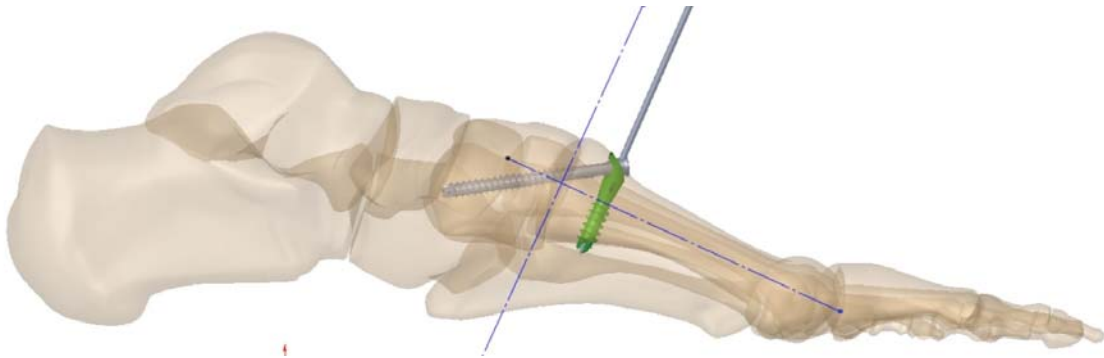


#### 2. Guidewire placement – parallel to the joint (5-10mm from the joint)

Confirm Lag Screw trajectory with X-Ray template against a fluoroscopic image.



**3. X-Post placement & subsequent Lag Screw placement** (same as in Surgical Technique)



**4. Second point of fixation (hypermobile joint in Lapidus)**

